Virtual Bronchoscopy for 3D CT Assessment and Endoscopic Guidance

William E. Higgins[1,2]
Anthony J. Sherbondy[1]
James P. Helferty[1]
Atilla P. Kiraly[1]
Geoffrey McLennan[2]
Eric A. Hoffman[2]
Janice Z Turlington[1]

[1]Penn State University
University Park, PA
16802

[2]University of Iowa
Iowa City, IA
52246

RSNA 2000
Chicago, IL
26 November 2000

infoRad

Learning Objectives:

1. Introduce the feasibility of PC-based virtual endoscopy for both 3D CT assessment and live bronchoscopy.

2. Demonstrate the concept of a multimedia case study for CT-based report generation and bronchoscopic guidance.

3. Describe a method for linking 3D CT data to live bronchoscopic video.

PENNSTATE

Exhibit Overview:

1. Overview of virtual bronchoscopy and our system (Virtual Navigator)

2. Stage-1 CT-only Analysis: **Human case**

3. Stage-2 Bronchoscopy examples:
   a. **Human case**
   b. **Phantom and animal studies**

Virtual Bronchoscopy (VB)

Input:

high-resolution 3D radiologic chest image

- ***virtual copy of chest anatomy***

Explore:

the virtual anatomy using computer

- ***permits unlimited "exploration"***
- ***no risk to patient***

PENNSTATE

Existing Virtual Bronchoscopic Systems

- Permit CT-only analysis
  - **No link to follow-on live bronchoscopy**
- Limited quantitative path planning to interesting sites
- Do not provide complete examination package
- Often require expensive computers

PENNSTATE

Our Proposal: Virtual Navigator

- Complete CT examination
- Guide live bronchoscopy
- Automate steps in CT assessment
- Inexpensive, PC-based

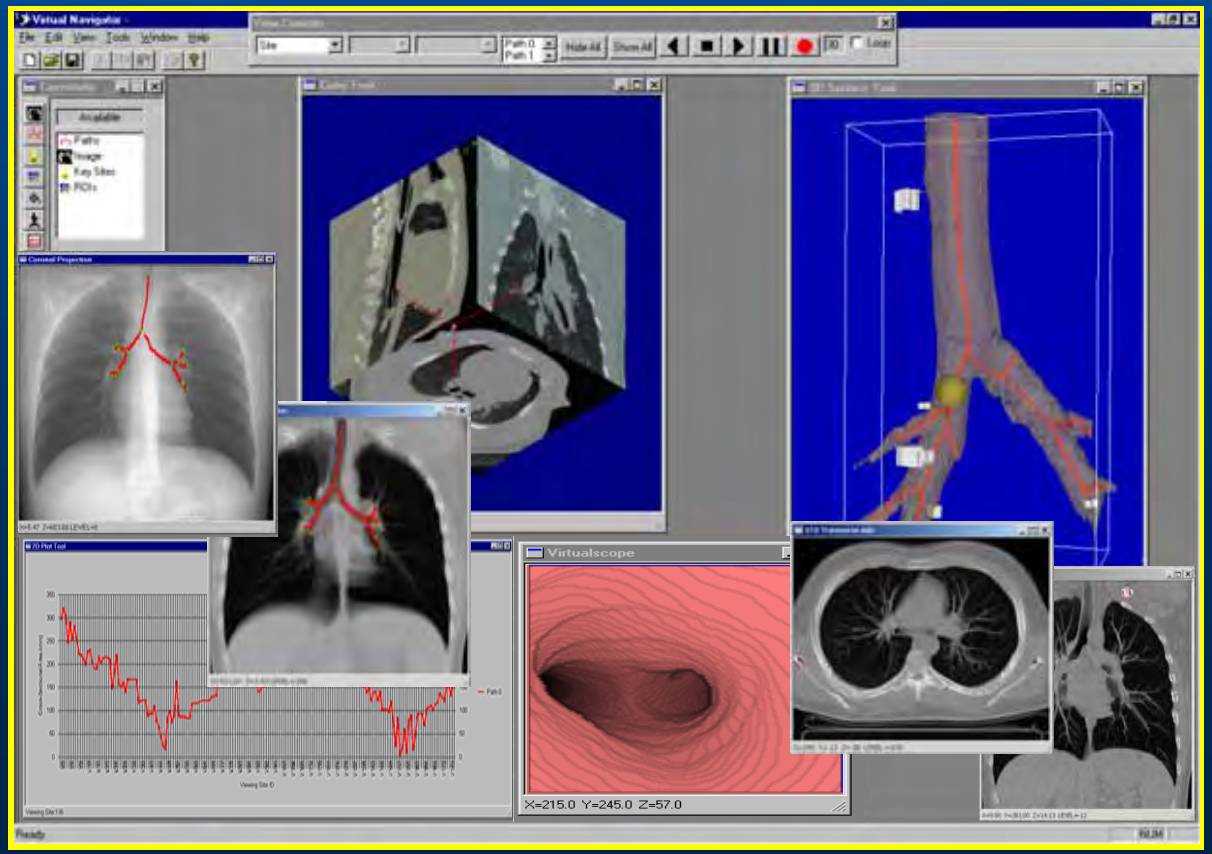

Case Study:

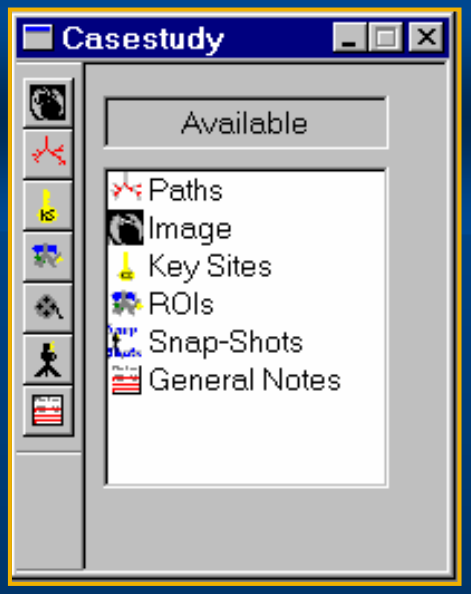

- Multimedia report
  - 3D CT assessment
- Supplemental plan
  - Guide bronchoscopy
- Build with Graphics/Processing Tools

Elements of Case Study:

1. Data Sources
   - 3D CT Image
   - Bronchoscopic Video
2. Data Abstractions
   - Root Site
   - Key Sites
   - Paths
   - Tree
3. Reporting Abstractions
   - Snapshots
   - Plots
   - Movies
   - Case Notes
   - Measurements

PENNSTATE

Graphics Tools - 1

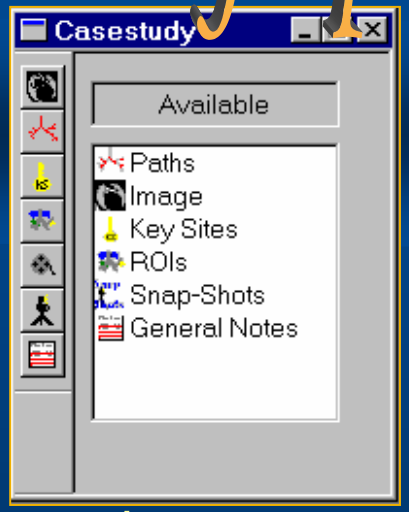

Study Manager

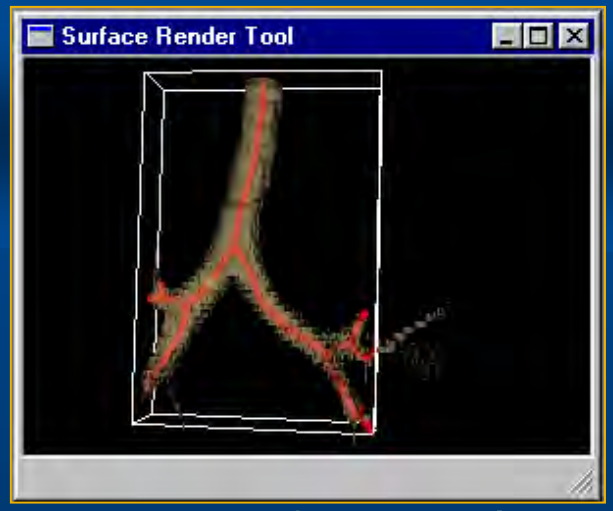

3D Surface Tool

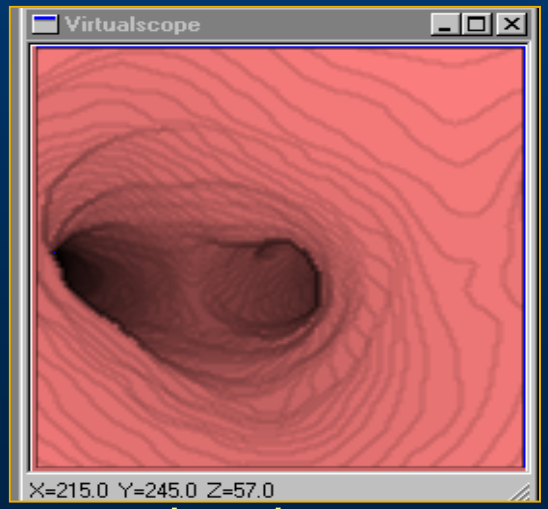

Virtualscope

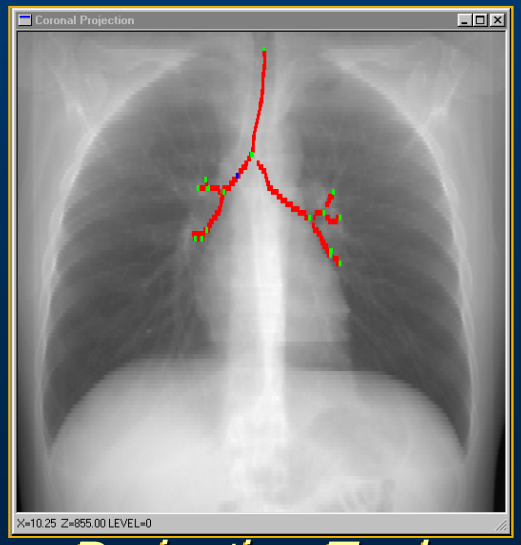

Projection Tools

Graphics Tools - 2

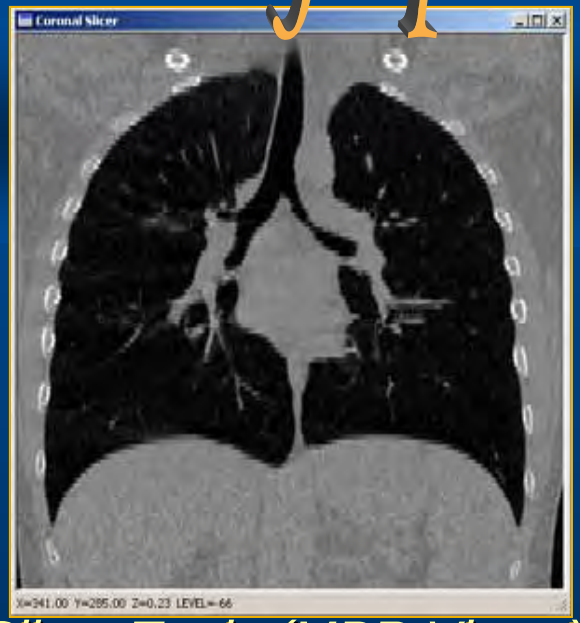

Slicer Tools (MPR Views)

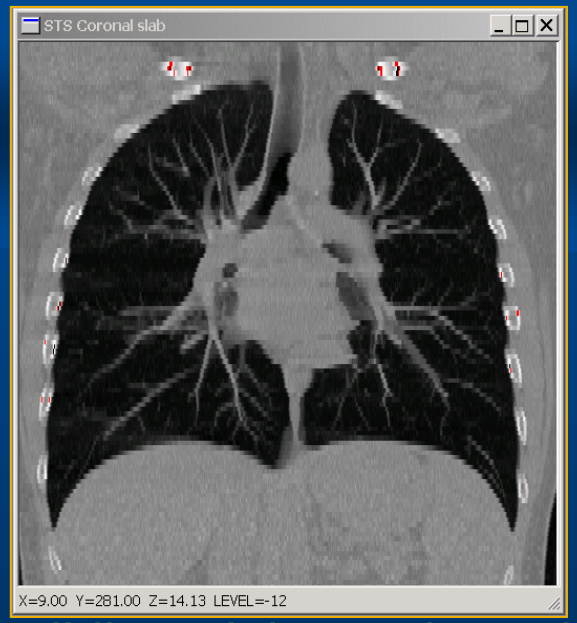

Sliding Slab Depth Tools

Oblique Cross Sections

Plot Tool

Graphics Tools - 3

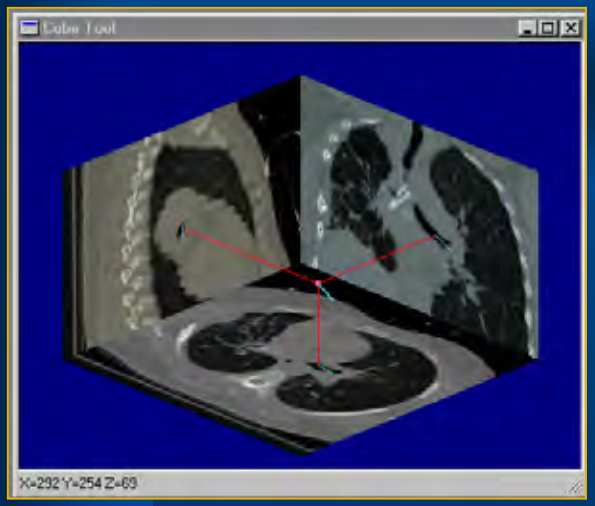

Cube Tool

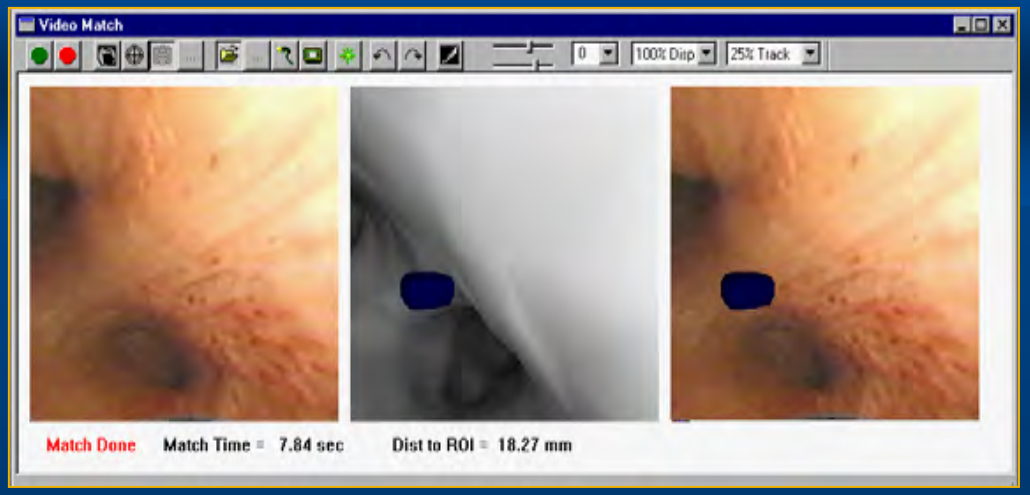

CT-Video Live Match Tool

Tube Viewer

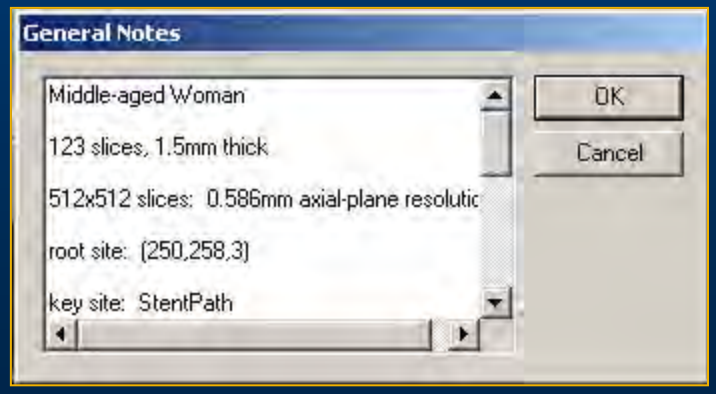

Notes Tool

PENNSTATE

Case Analysis using the Virtual Navigator

Stage 1: CT Assessment

Examine case and plan bronchoscopy

Stage 2: Bronchoscopy

Virtual CT guidance of live bronchoscopy

PENNSTATE

Examination Stages

Stage 1: CT Assessment

1. Create new Case Study.
2. Compute guidance data.
3. Build complete Case Study.

Stage 2: Bronchoscopy

1. Load Case Study.
2. Set up graphical tools.
3. Perform virtual-guided bronchoscopy.

PENNSTATE

Stage 1: CT Assessment

1. Create new Case Study.
   - ✓ a. Build Case Study registry
   - ✓ b. Set up for computing guidance data

✓ 2. Automatically compute guidance data.

✓ 3. Build complete Case Study.

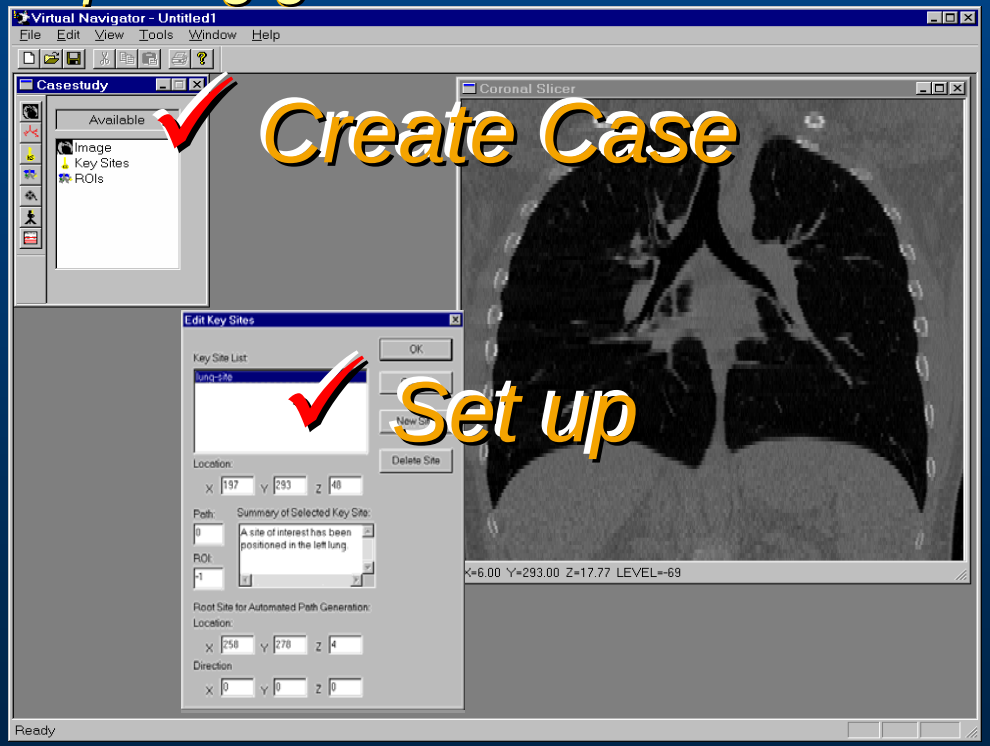

Stage 1: CT Assessment

Determine global 3D interior detail

Extract paths through airways.

Study interior path dynamics.

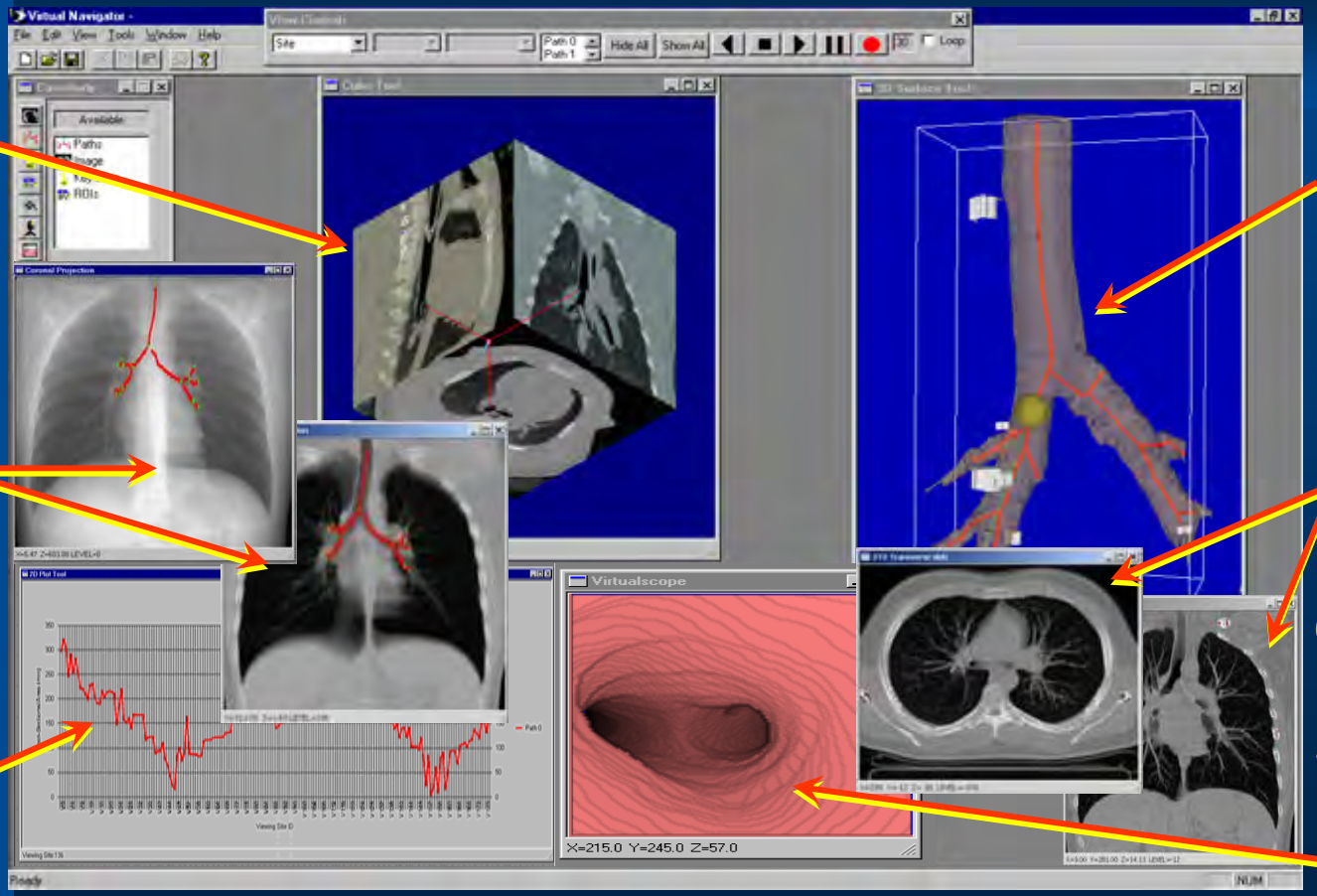

Render airway tree with paths, traverse pathways.

View structure relations within their environment.

Travel through virtual airway paths.

Example 1 Tracheomalacia CT Assessment

Patient underwent

EBCT scan (Electron Beam):

- single 20-sec breath-hold
- 133 contiguous slices

Reconstructed 3D CT image:

- Slice = 512X512 voxels
- Slice thickness =1.5mm
- axial-plane [x-y] resolution = 0.586mm.

Virtual Navigator shows

- Characteristics of collapse
- Condition of extended bronchial pathways

PENNSTATE

Tracheomalacia

Stage 1: CT Assessment

MPR Views Indicate Global 3D position

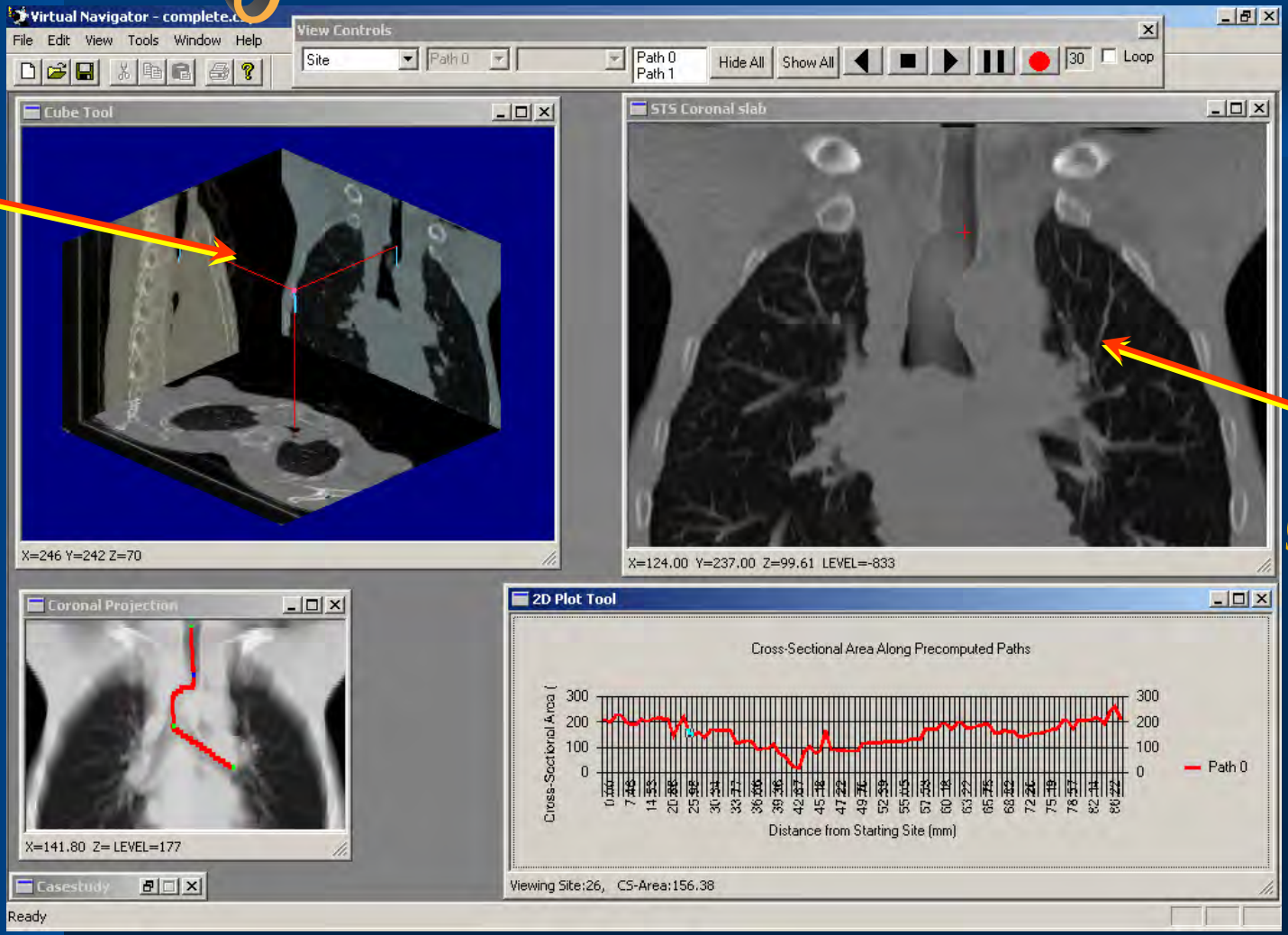

Depth-weighted Slab shows geometry

Same 3D site focused on by all tools.

Tracheomalacia

Stage 1: CT Assessment

Selected 3D site (BLUE DOT) Highlighted on Five different tools at once.

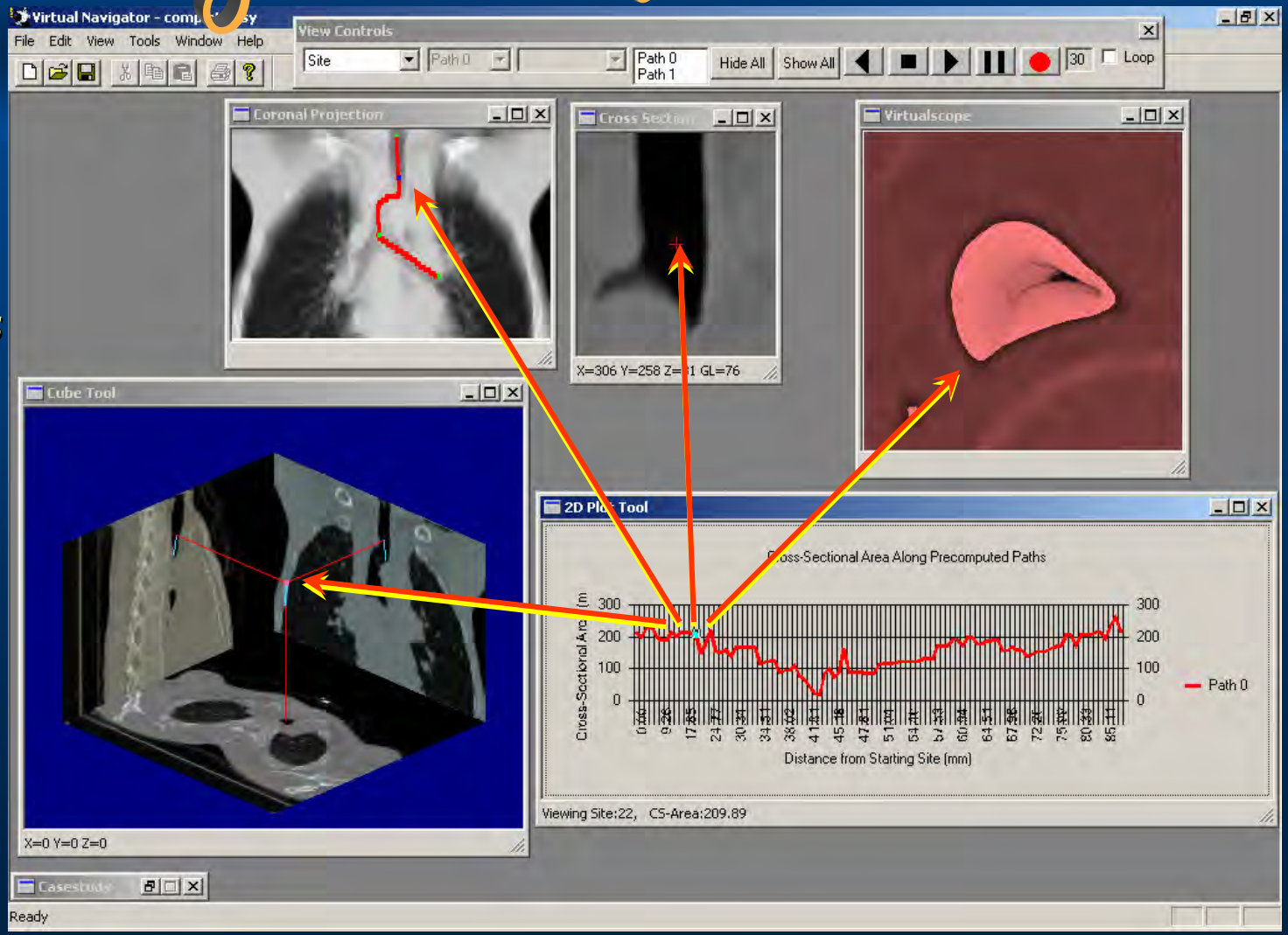

Tracheomalacia Assessment

Computed Virtual Path

on coronal weighted-sum projection

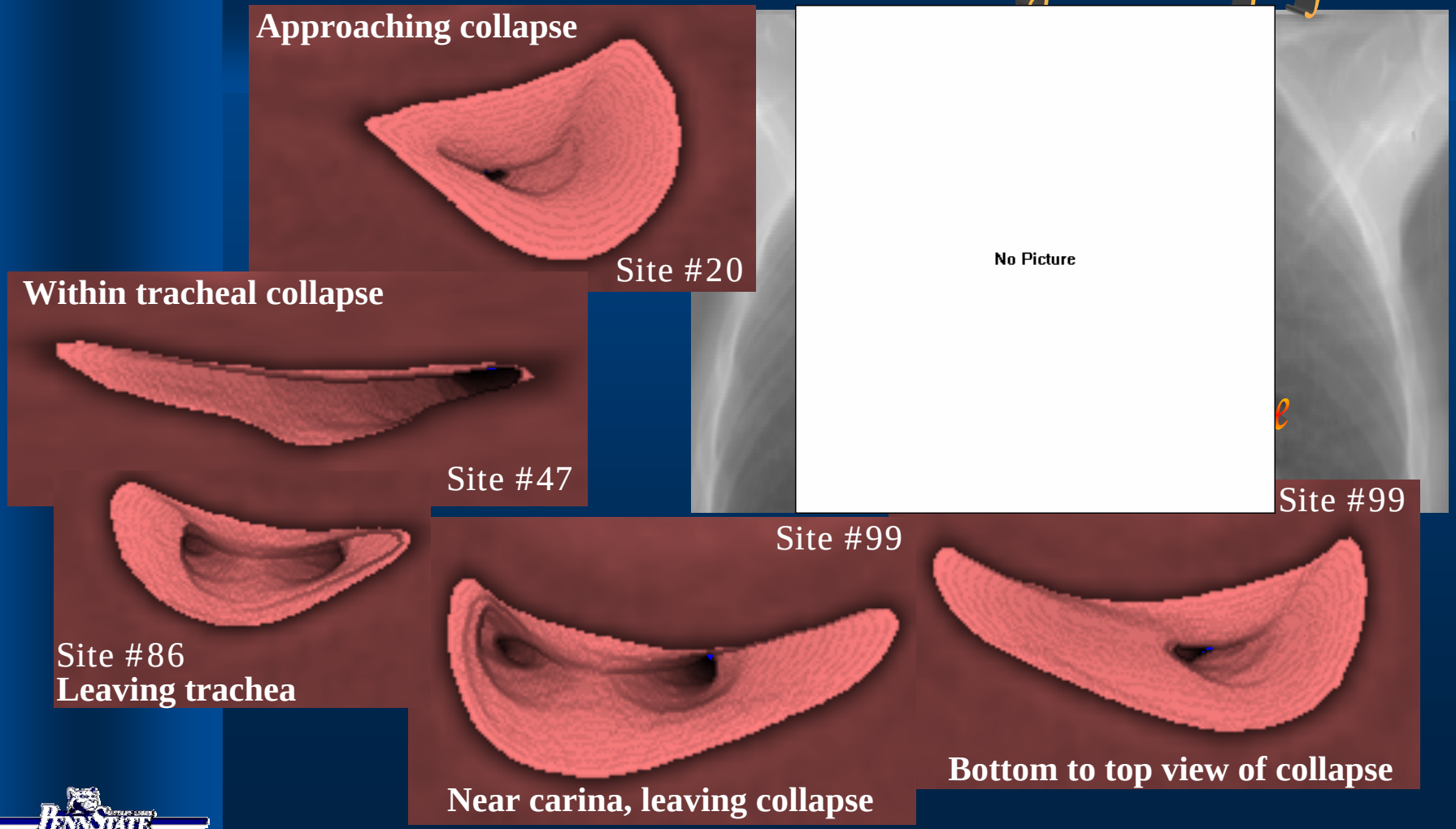

Tracheomalacia Assessment

Airway Cross Sectional Area

Plot along Airway path

Plot clearly shows section where blockage occurs

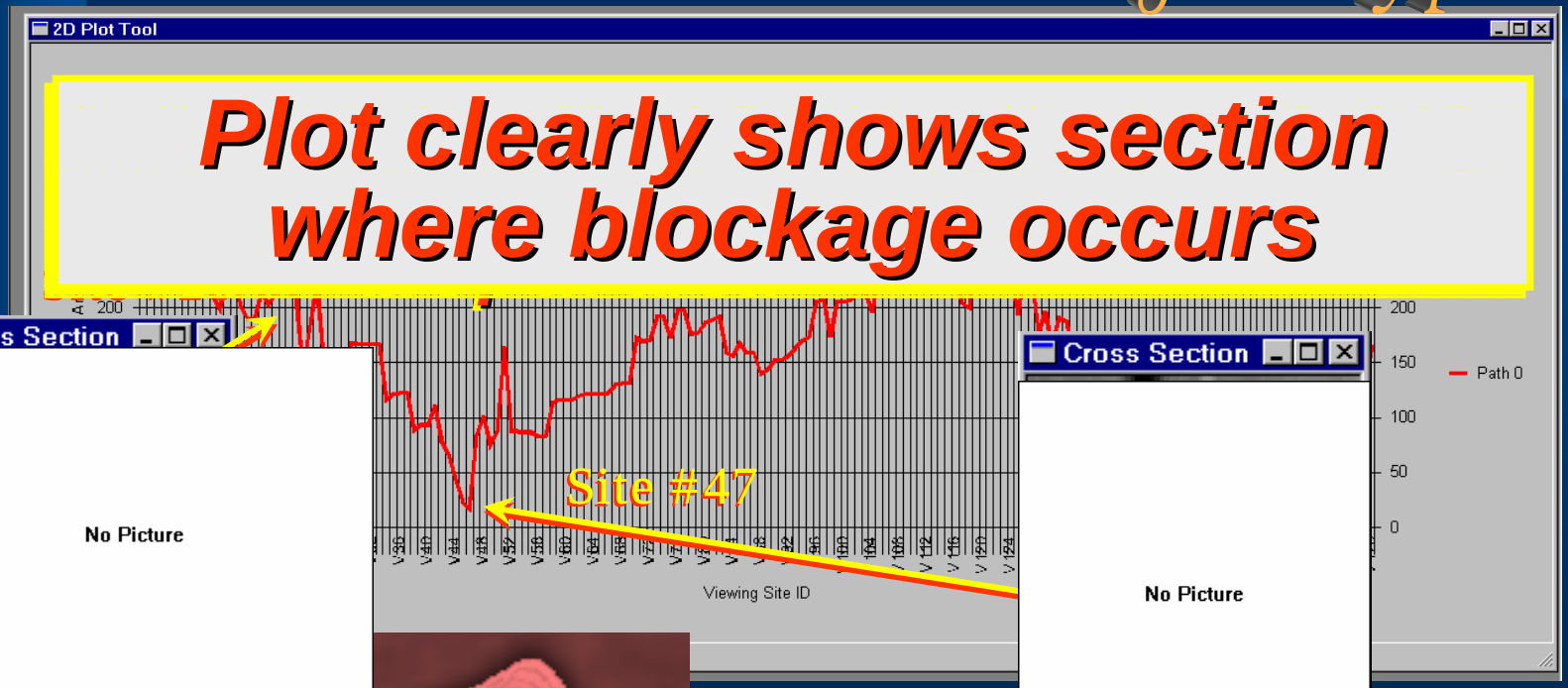

Approaching collapse

Within tracheal collapse

Tracheomalacia Assessment

Captured Snapshots of Pathology

Pathology documented by captured Depth-Slab snapshots.

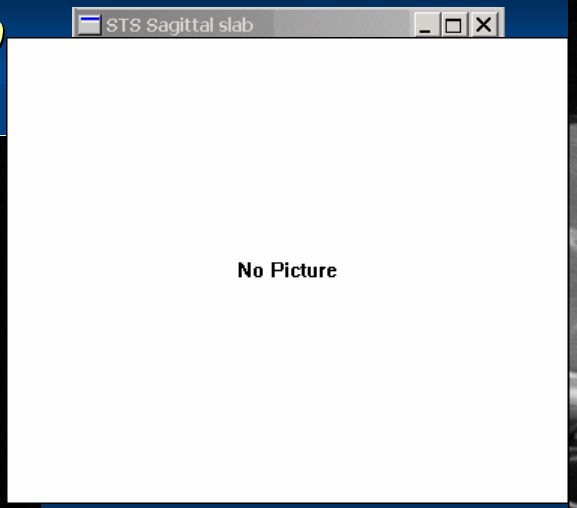

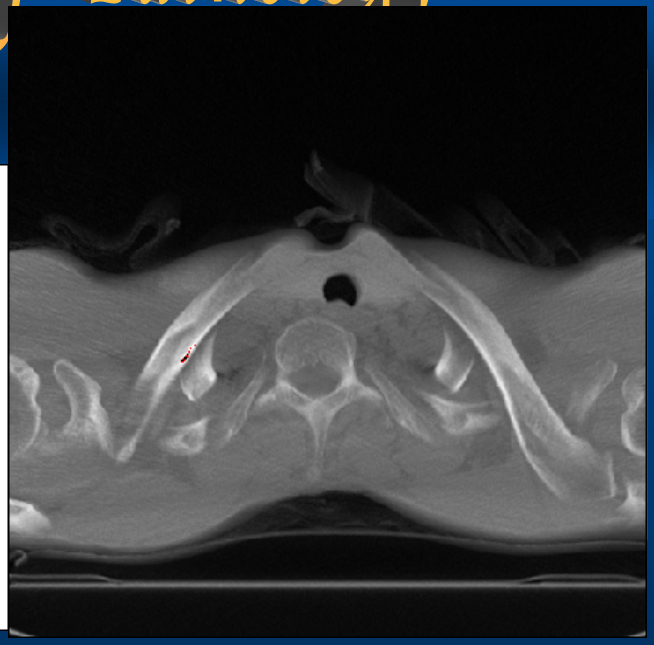

Extent of collapse shown in rendered Airway tree.

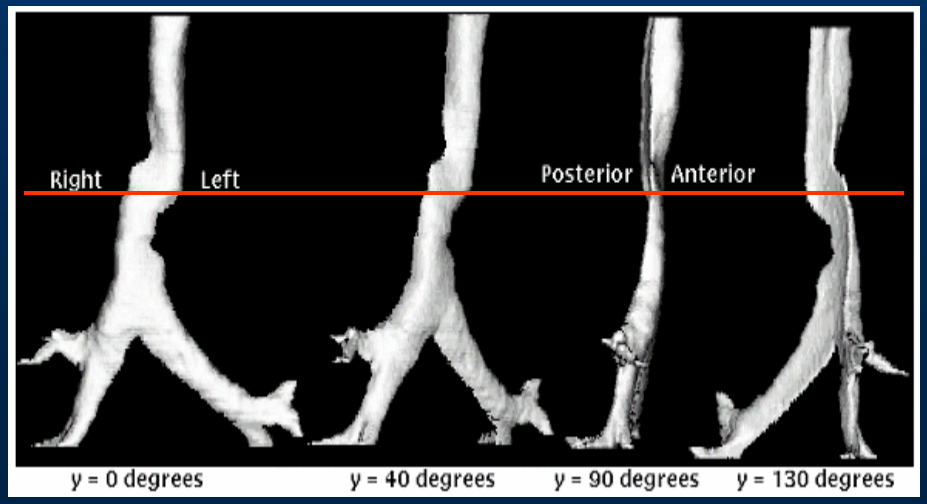

Example 2 Stent Modification

CT Assessment + Bronchoscopy

Patient underwent

EBCT scan (Electron Beam):

- single 20-sec breath-hold
- 133 contiguous slices

Reconstructed 3D CT image:

- Slice = 512X512 voxels
- Slice thickness =1.5mm
- axial-plane [x-y] resolution = 0.586mm.

Virtual Navigator shows

- Details of existing stent
- Basis for intervention analysis
  (laser therapy was performed)

PENNSTATE

Stent Modification

Stage 1: CT Assessment

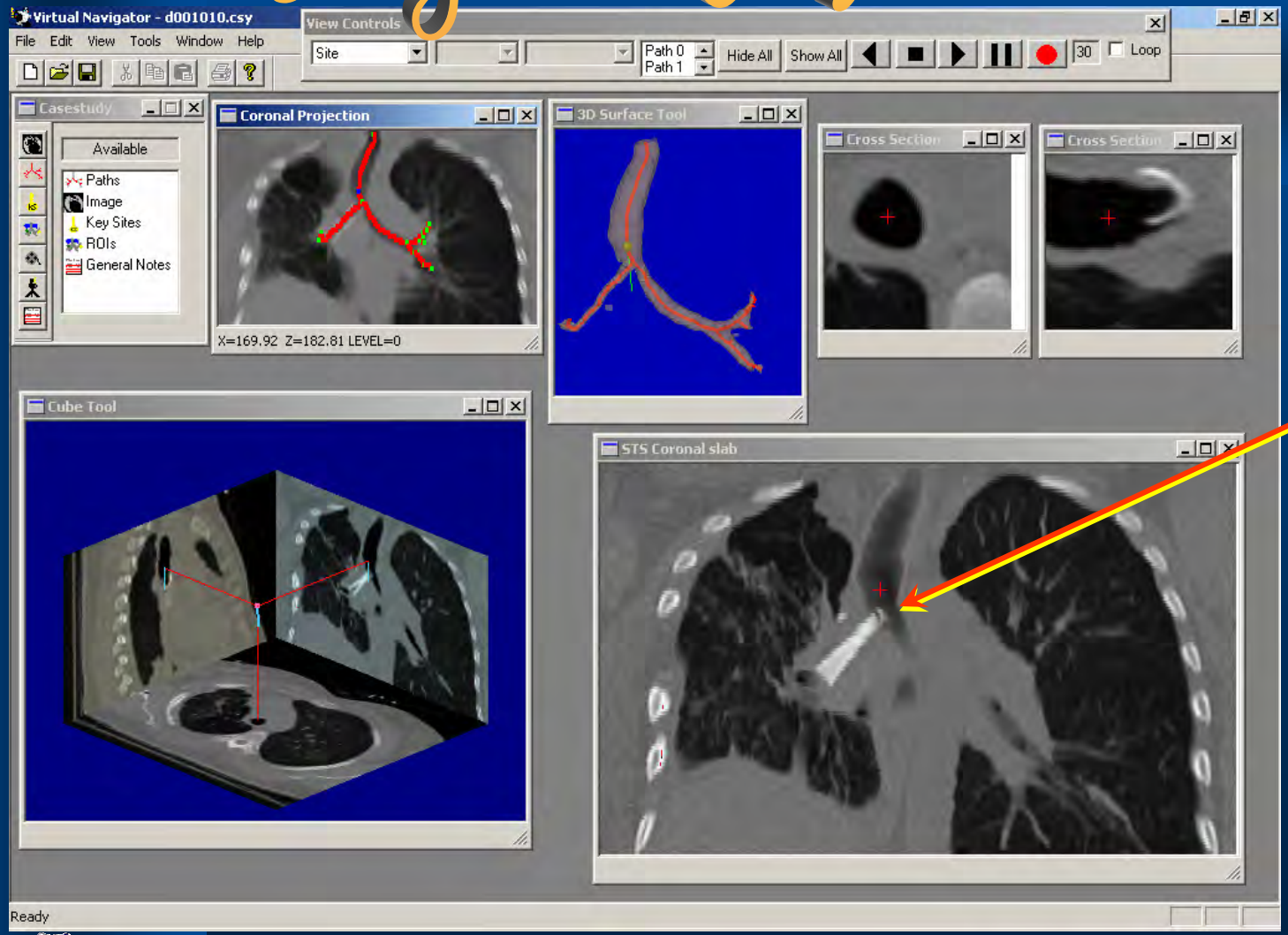

Stent visible In this and other views

Same 3D site focused on by all tools.

Stent Modification

Stage 1: CT Assessment

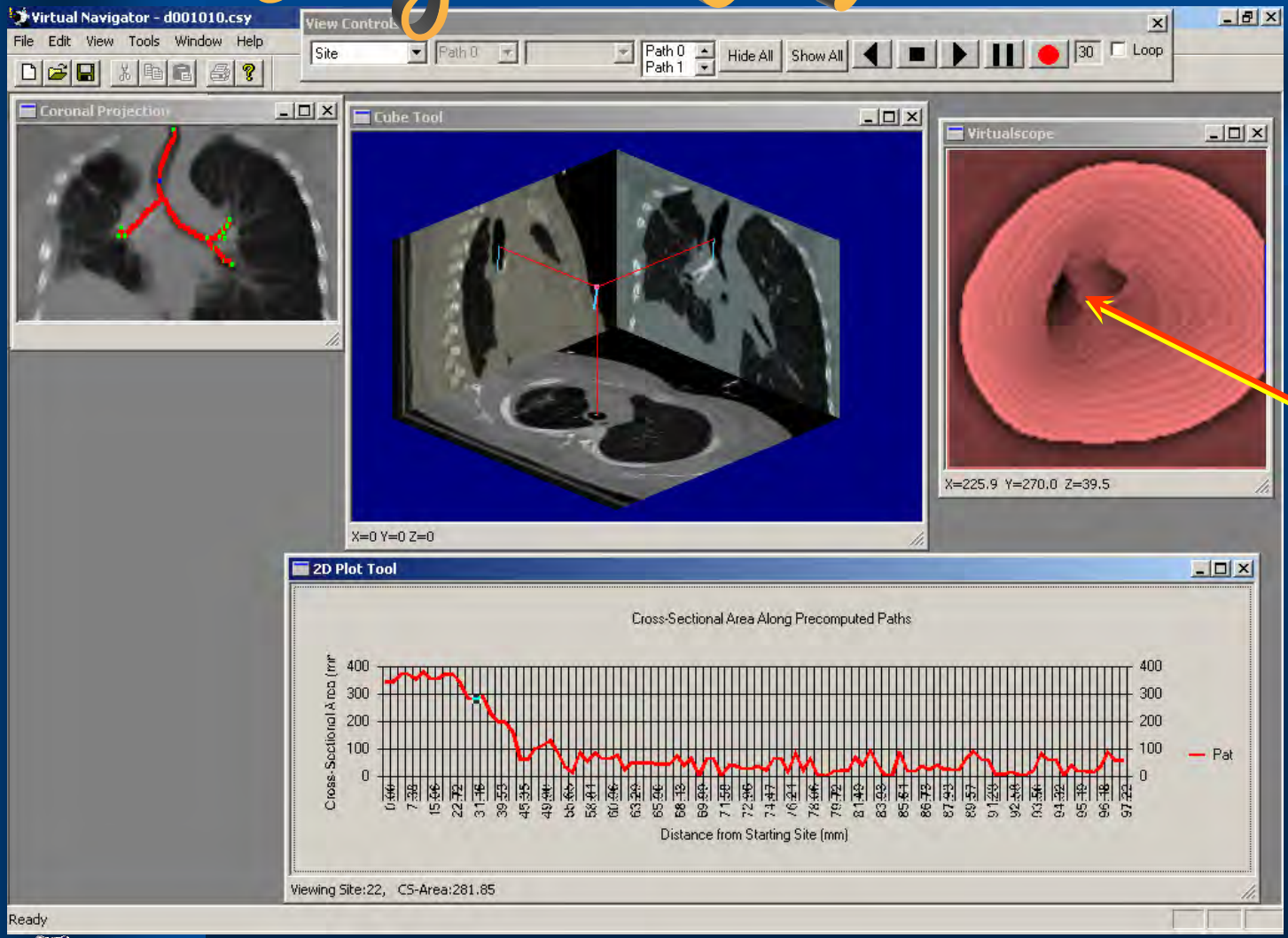

Stent encroaching on main carina

We now present

the use of

Virtual Navigator

for live bronchoscopy.

Stage 2: Bronchoscopy

1. Load Case Study.
2. Set up graphical tools.
3. Perform virtual-guided bronchoscopy.

Virtual Guidance of Live Bronchoscopy

Coronal Projection shows extracted airway tree

Virtual data guides airway traversal.

Video Match Tool shows a matched point between

1. **CT rendering of airway region** (ROI rendered)
2. **LIVE bronchoscope video**
3. **Corresponding videobronchoscopy** (ROI superimposed)

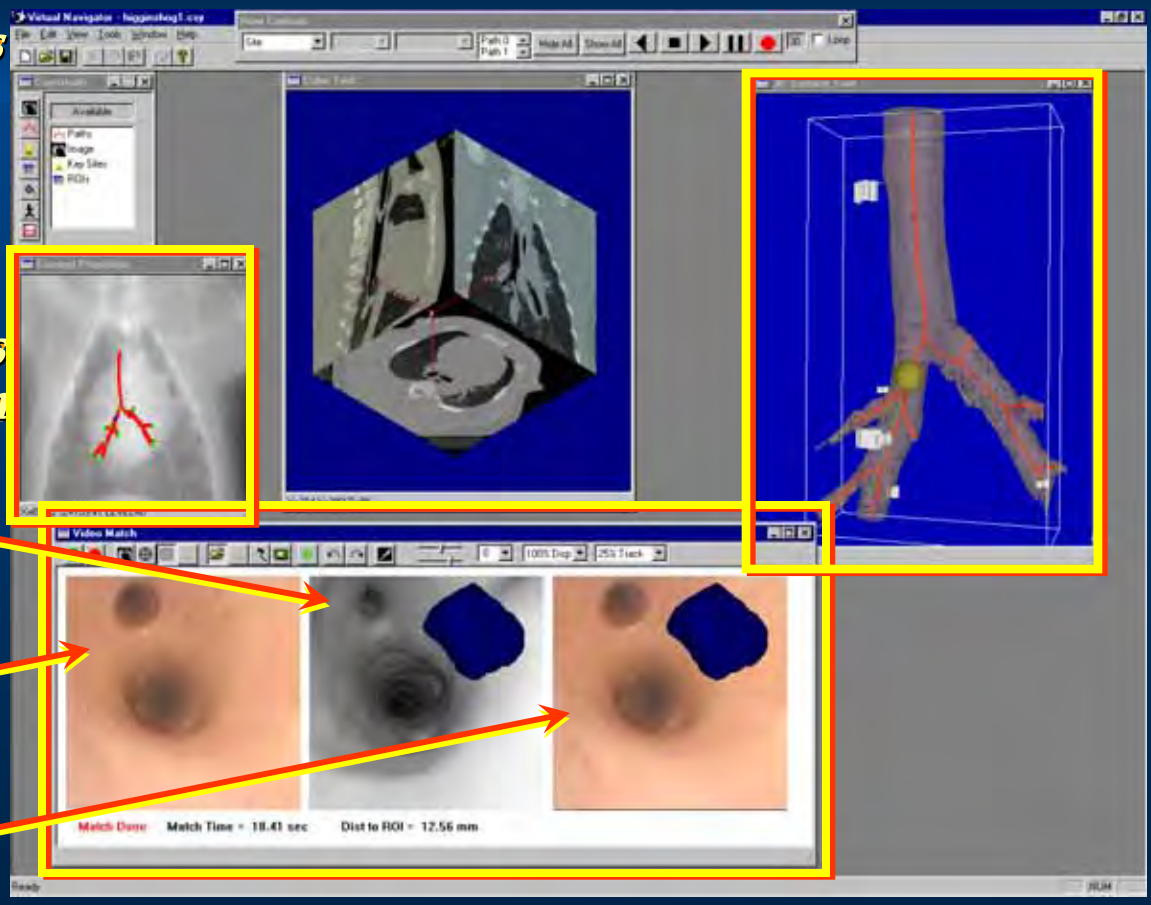

PENNSTATE

We now present

Virtual Navigator

applied to three bronchoscopy studies:

1. **Phantom**
2. **Animal**
3. **Human**

Phantom Study
Virtual Guidance of Live Bronchoscopy

Rubber phantom

Experimental set-up:
physician was blind to phantom

PENNSTATE

Phantom Study
Virtual Guidance of Live Bronchoscopy

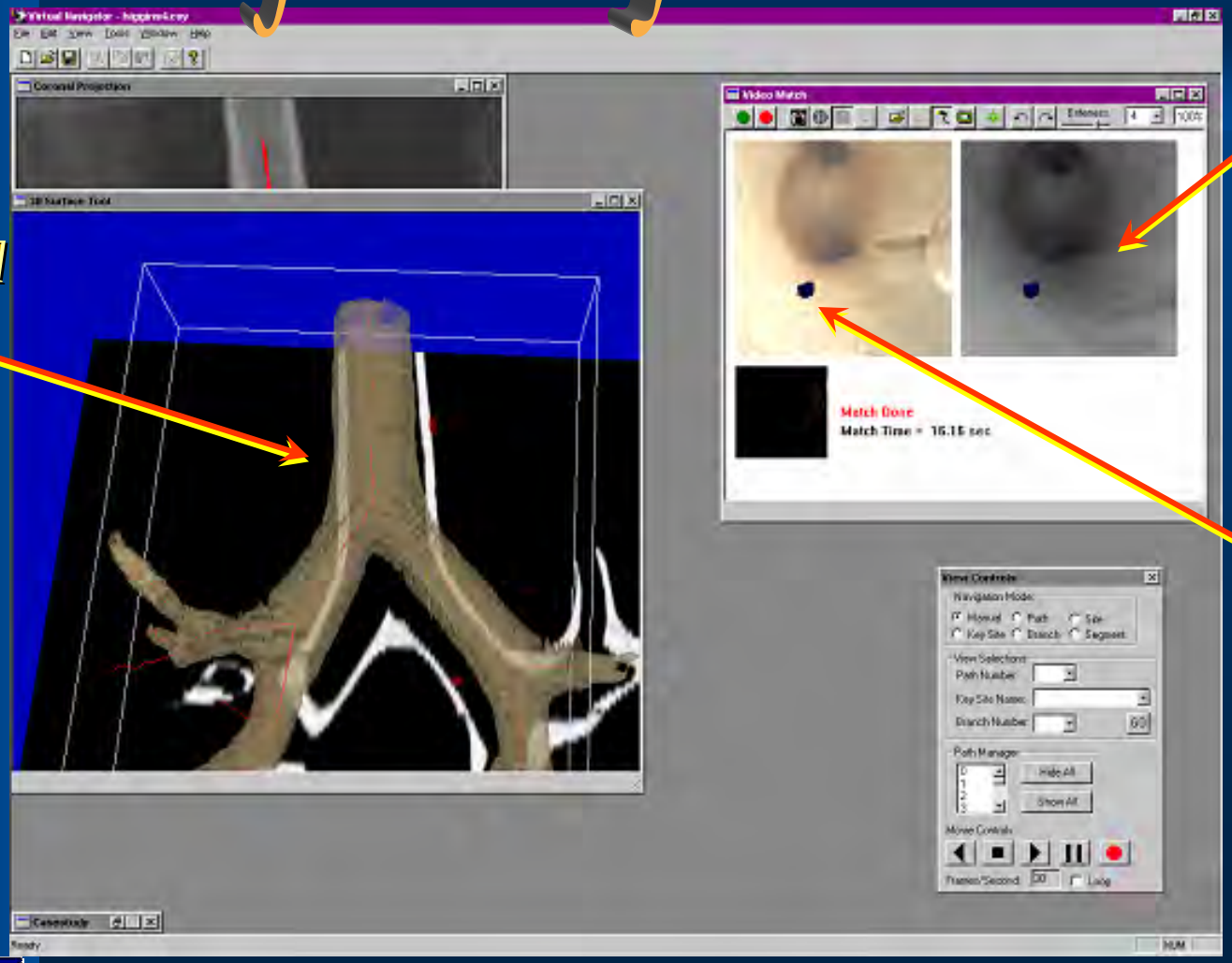

Phantom Study
Numerical Results of Virtual Guidance

	Physician #1 (trial 1)		Physician #1 (trial 2)		Physician #2	
	Distance (mm)	Time sec.	Distance (mm)	Time sec.	Distance (mm)	Time sec.
Average	2.18	12.613	1.73	9.672	2.01	10.91
Std Dev	1.09	8.865	0.97	8.789	0.89	5.325

Note: Distance and time measured to match each ROI target.
Distance measured from line extrapolated from the needle direction to metal bead edge.

- **Average biopsy error: 1.98 mm**
- **Average match time: 11.065 sec.**

PENNSTATE

Animal Study
CT-Video Matching Results

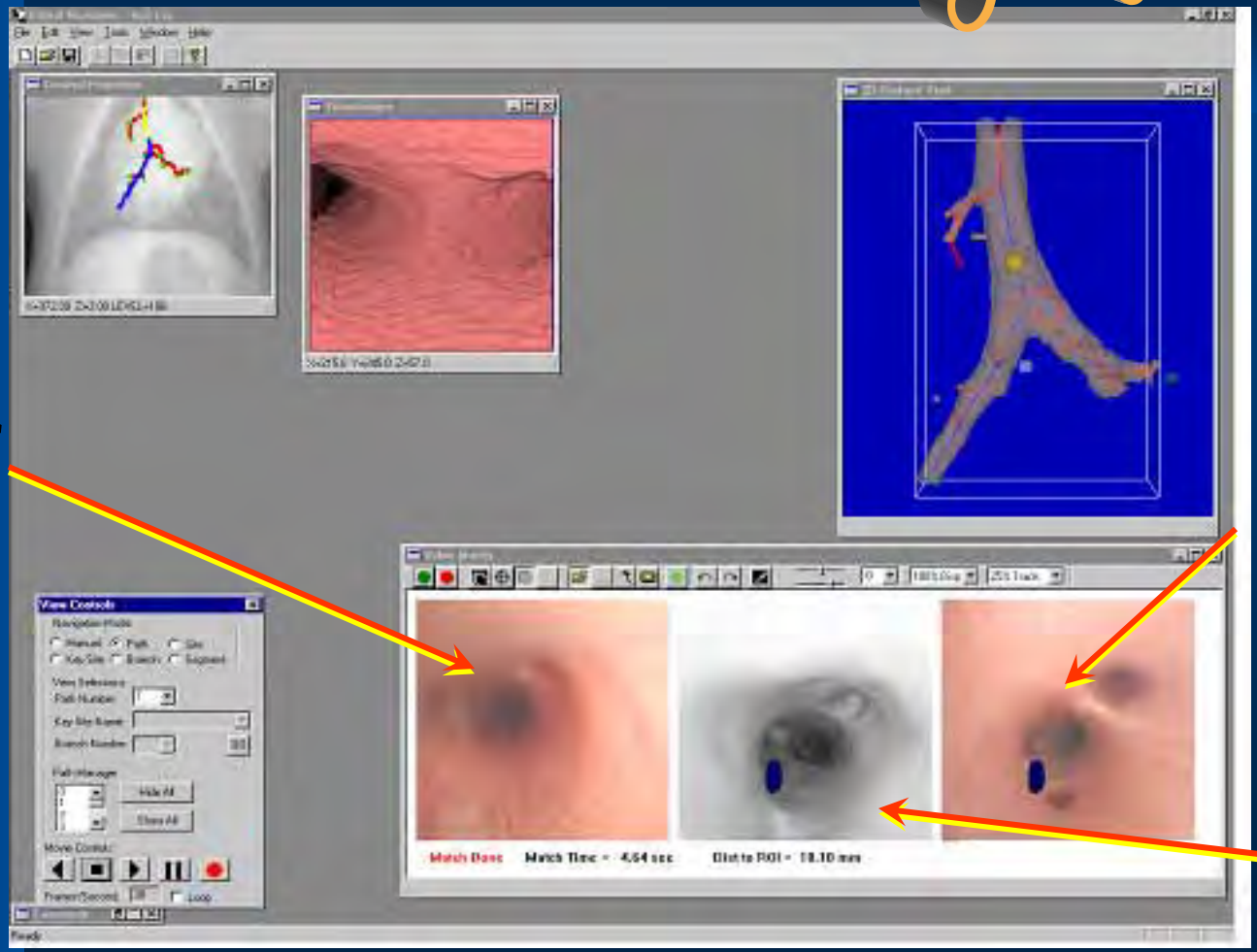

Animal Study
CT-Video Matching Results

Planned site *from CT analysis.*

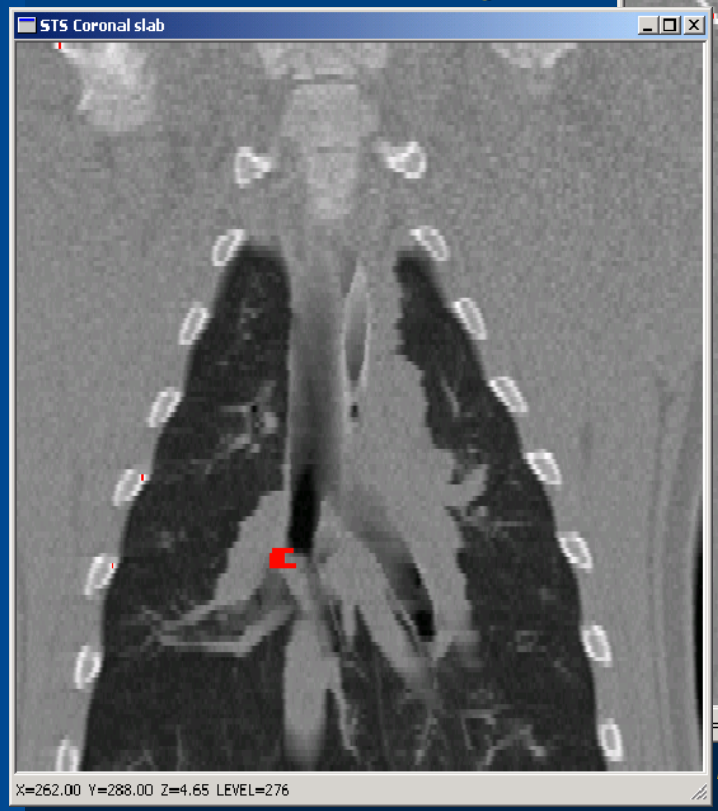

Actual site *after guided dye marker placement.*

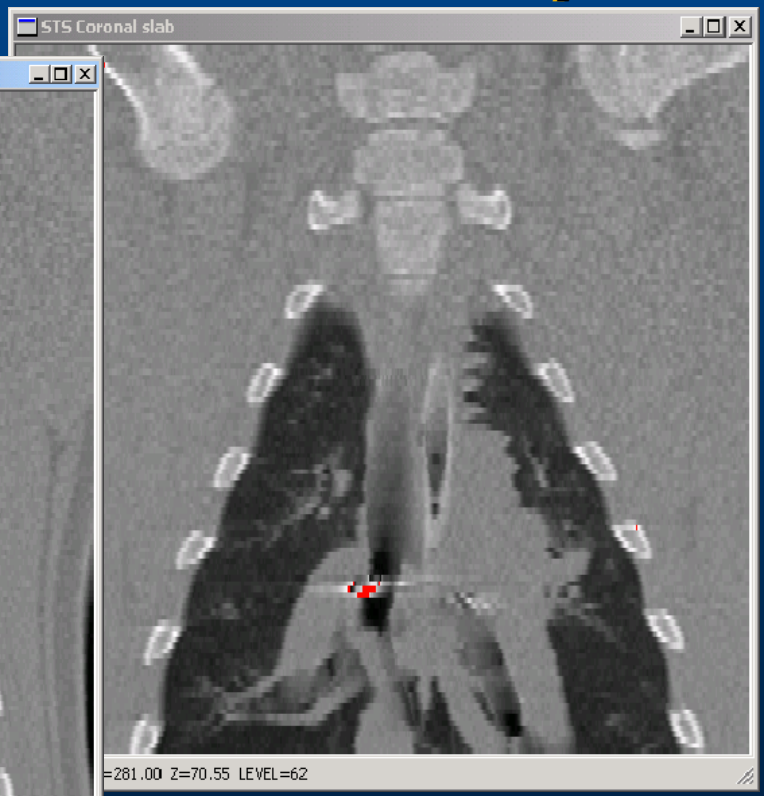

Note: ***Snapshots are misaligned to compensate for differing placement during CT scanning.***

PENNSTATE

Stage 2: Live Human Bronchoscopy

Live Bronchoscopic Video match with Rendered CT Airway

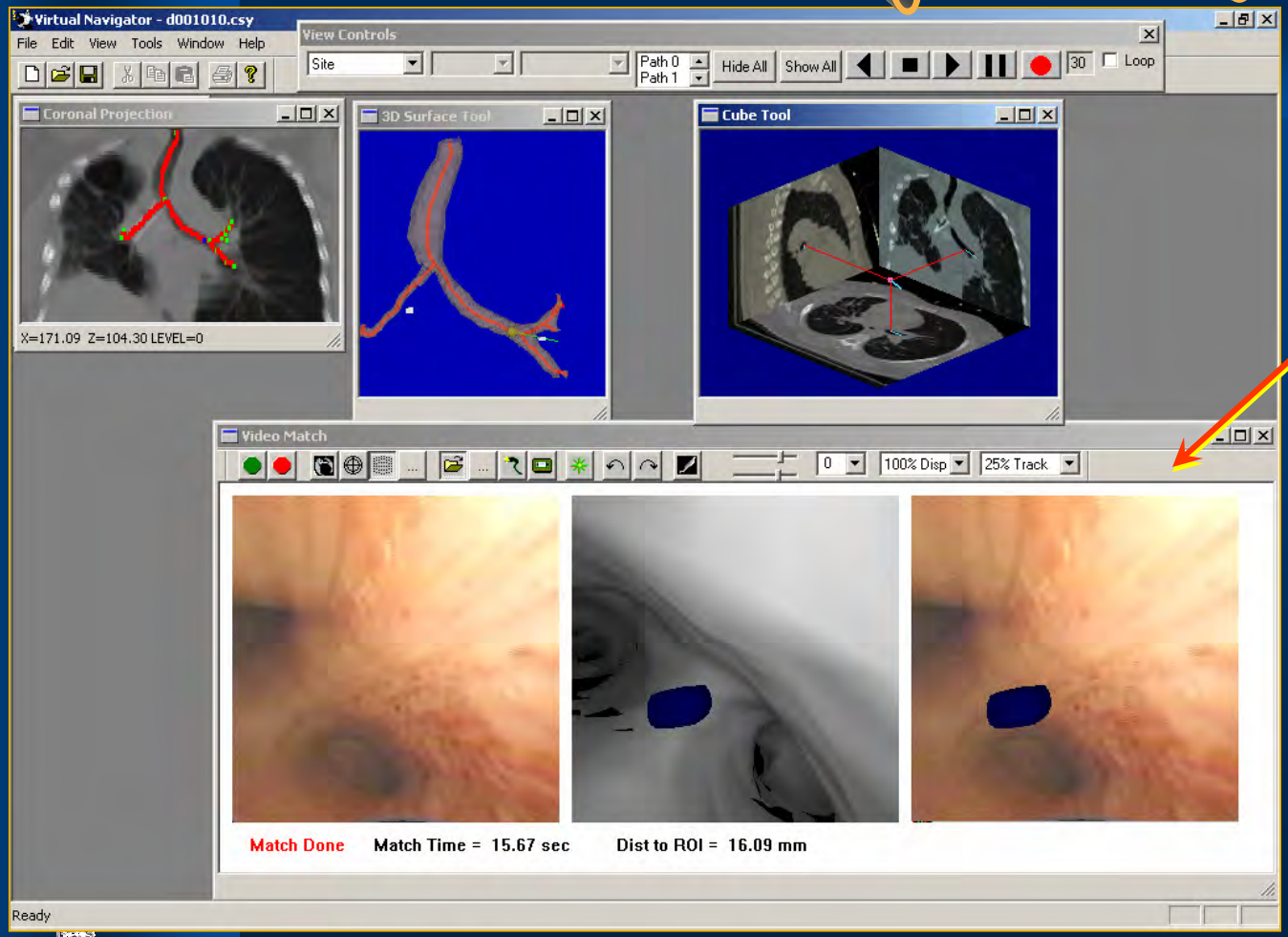

Bronchoscope video matched to rendered CT during live procedure.

(End)

Acknowledgements

Research supported by grants from:

National Cancer Institute of the ***NIH***
(grant CA74325)

National Center for ***Research Resources*** of the ***NIH***
(grant RR11800)

Whitaker Foundation

Thank You!

(This presentation will repeat in 5 seconds.)