Image-Guided Bronchoscopic Sampling of Peripheral Lesions: A Human Study

W.E. Higgins,[1] R. Bascom,[2] J.D. Gibbs,[1,3] M.W. Graham,[1,4] D.C. Cornish,[1] and R. Khare,[1]

Penn State University, [1]College of Engineering, [2]College of Medicine, [3]Broncus Technologies, Inc., [4]Google, Inc.

***ATS 2010*, New Orleans, LA**

1. Background

Reliable biopsy of peripheral nodules is important for lung cancer diagnosis. Peripheral procedures are difficult, however, as the bronchoscopist must navigate through many airway generations to reach an appropriate biopsy site and the target nodule is typically hidden behind the airway walls.[1] CT fluoroscopy and electromagnetic-navigation bronchoscopy have been proposed to assist the bronchoscopist.[2-3] Recently, however, Virtual Bronchoscopic (VB) guidance derived solely from a patient's multidetector CT (MDCT) chest scan has shown promise towards improving peripheral bronchoscopy performance without requiring significant additional hardware.[4-6] We had previously shown that our computer-based virtual navigation (VN) system provides reliable guidance and is feasible for human peripheral nodules.[7] We now present final results for a human study of the VN system for peripheral lesion biopsy.

2. Materials and Methods

We consented and enrolled 30 patients with focal lesions, suspected lung cancer and available MDCT scans. The chest scans, generated by either a Siemens Sensation or Emotion scanner, were reconstructed at a resolution of 0.5 mm spacing with 0.75-mm-thick 2D axial-plane sections; axial-plane resolution was between 0.52 mm and 0.92 mm. We used the VN system for off-line procedure-planning and live bronchoscopic guidance, as described below.[6] Primary study outcomes for each region of interest (ROI) were: 1) Navigation success: ability of the system to lead the bronchoscopist along the correct route; 2) Sampling success: collection of a satisfactory tissue sample (pathologist interpretation).

Stage 1: Procedure planning

The bronchoscopist identified a ROI on a patient's MDCT chest scan. Next, automatic computer-based methods extracted the 3D airway-tree, computed the endoluminal surfaces of the airways, defined a 3D endobronchial route leading to the ROI, and produced an interactive pre-bronchoscopy report enabling pre-procedure review of guided images by the bronchoscopist.

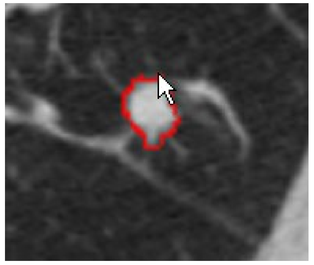

The bronchoscopist indicates a target nodule (case 20349-3-25)

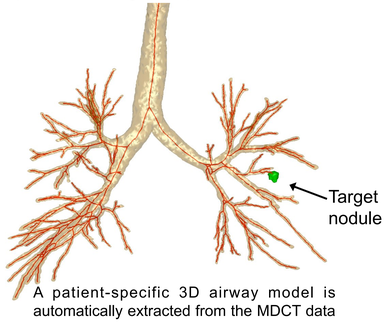

A patient-specific 3D airway model is automatically extracted from the MDCT data

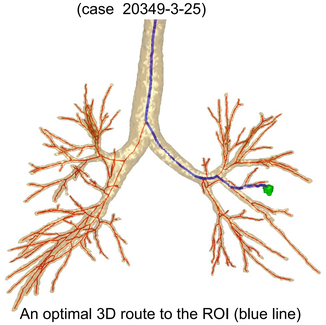

An optimal 3D route to the ROI (blue line) is determined automatically

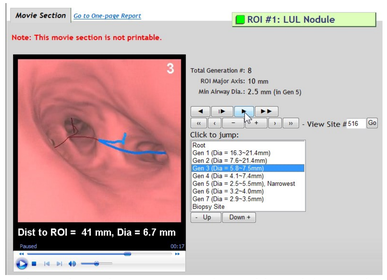

A pre-bronchoscopy report provides pictures of each bifurcation along the route and an interactive movie of the entire route to preview the procedure.

Stage 2: Live image-based bronchoscopic guidance

In the bronchoscopy suite, a guidance computer interfaced to the bronchoscope. We employed either a 2.8-mm-diameter Olympus BF Type XP160F ultrathin videobronchoscope, a 4.9-mm-diameter Olympus BF Type P180 true-color videobronchoscope, or a 6.0-mm-diameter Pentax EB1570K videobronchoscope. Sampling procedures involved either a brushing, bronchoalveolar lavage, or a needle (only available with the 4.9-mm Olympus bronchoscope or the Pentax bronchoscope). During the procedure, the bronchoscopist maneuvered the bronchoscope along the predefined endobronchial route using the continuously-updated graphical information provided by the computer (Figure 1). The computer also displayed unambiguous graphical information at the final biopsy site (Figure 2).

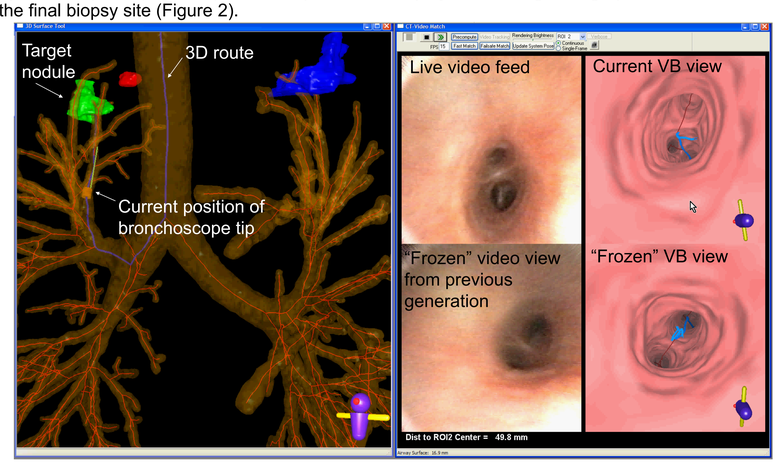

Figure 1: Computer display of the VN system captured during a live procedure (case 20349-3-28). The blue line is the route to the green target nodule. The line clearly and unambiguously leads the bronchoscopist to the target nodule.

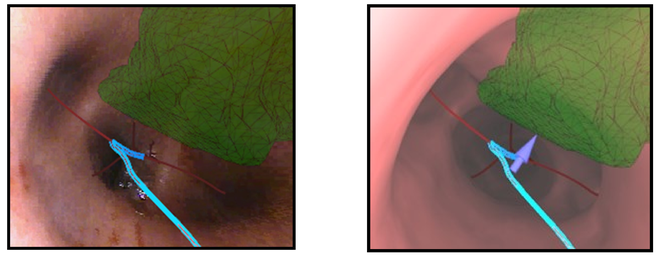

Figure 2: Example of guidance information provided by VN system at the final biopsy site (case 20349_3_38). The blue arrow indicates the end of the endobronchial route and points to the center of the green target nodule.

3. Results

The VN system fit smoothly into the clinical workflow, with required physician interaction limited to indicating target ROIs and previewing the image-guided procedure with the pre-bronchoscopy report. The system functioned properly and introduced no safety issues for all cases. A summary of the results appear below.

- 69 target ROIs considered for the 30 patients:
  - 62 diagnostic sites requiring a tissue sample (22 nodules, 4 masses, 16 infiltrates, 3 ground-glass opacity, 4 BAL sites, 7 lymph nodes, 13 other (including cavitary lesions, collapsed airways, 1 cavity wall, and 1 foreign body)
  - 7 sites where only visual inspection was required.
- Navigation success: 91% (63/69)
  - 84%: bronchoscope navigated to within 2 generations of ROI
  - 67%: bronchoscope navigated to within 1 generation of ROI
  - 27%: bronchoscope navigated to the final airway generation
- Satisfactory sample rate for diagnostic sites: 90% (56/62) (TBNA, brushing, forceps, or BAL)
- Mean time until first sample: 5:15 ± 5:06 (median: 3:40 range: 0:25 – 32:07)

Predicted Depth equals Guided Bronchoscopy Depth

	No. of Airways		
Procedure Planning - Depth of Computed Routes	Mean	Median	Range
All target sites (69)	8.7 ± 2.7	8	4-14
Sites examined only via ultrathin bronchoscopy (45)	9.8 ± 2.2	9	6-14
Sites examined with a large bronchoscope (24)	6.7 ± 2.2	6	4-11
Predicted navigable depth - all target sites	7.0 ± 2.2	7	4-14
Guided Bronchoscopy - Bronchoscope Insertion Depth			
All target sites	7.1 ± 2.4	7	3-13
Sites examined only via ultrathin bronchoscopy	8.0 ± 2.0	8	4-13
Sites examined with a large bronchoscope	5.4 ± 2.0	5	3-10

	Bronchoscopes Used				Successful Navigation				Satisfactory Sample			
Location	Ultrathin	Large	Both	Total	Ultrathin	Large	Both	Total	Ultrathin	Large	Both	Total
RUL	12	4	2	18	11	4	2	17	11	3	1	15
RML	7	3	2	12	6	3	2	11	5	3	2	10
RLL	9	2	1	12	8	2	1	11	7	1	1	9
LUL	14	5	3	22	13	5	3	21	13	4	3	20
LLL	3	2	0	5	2	1	0	3	2	1	0	3
Total	45	16	8	69	40	15	8	63	38	12	7	57

Procedure Planning: Depth of Computed Routes						
	Current study				Previous study[5]	
	All sites		Ultrathin		Ultrathin	
Lobe	No.	Depth	No.	Depth	No.	Depth
RUL	18	7.4±2.1	12	8.4±1.6	20	7.0±1.2
RML	12	9.3±2.9	7	10.1±2.9	7	8.6±1.1
RLL	12	10.8±2.7	9	11.4±1.4	23	7.6±1.2
LUL	22	8.3±2.7	14	9.7±2.2	21	7.2±0.6
LLL	5	9.2±2.3	3	10.0±2.6	14	7.4±1.6
Total:	69	8.7±2.7	45	9.8±2.2	85	7.5±1.2

Guided Bronchoscopy: Depth of Bronchoscope Insertion						
	Current study				Previous study[5]	
	All Sites		Ultrathin		Ultrathin	
Lobe	No.	Depth	No.	Depth	No.	Depth
RUL	18	5.9±1.8	12	6.8±1.3	20	5.0±1.3
RML	12	7.7±1.9	7	8.0±1.6	7	6.9±0.9
RLL	12	8.9±2.9	9	9.6±2.8	23	5.9±1.3
LUL	22	6.9±2.3	14	8.1±1.7	21	5.4±1.3
LLL	5	6.2±1.9	3	7.0±1.0	14	6.1±1.4
Total:	69	7.1±2.4	45	8.0±2.0	85	5.7±1.3

When compared to Shinagawa 2007 Study,[5] VN System enables:

1. Significantly deeper procedure plans (9.8 generations vs. 7.5 generations; $p<0.0001$)
2. Significantly deeper bronchoscopy insertion depth (8.0 generations vs. 5.7 generations; $p<0.0001$)

- Reasons for 6/69 Navigation errors:
  - 3 cases: Live video feed and current VB view were not synchronized
  - 1 case: Difficult bronchoscope maneuver required. The bronchoscopist executed the maneuver, then the bronchoscope slipped out of the correct airway and proceeded into an incorrect airway.
  - 1 case: Incorrect rotation of virtual view misguided the bronchoscopist
  - 1 case: Bifurcation missed when bronchoscope camera lens was occluded by fluid
- General comments
  - Bronchoscope device limitations prevented the bronchoscopist from maneuvering the bronchoscope to the final site in some cases. This also caused the time to navigate the bronchoscope to some ROIs to be long. Recent developments of bronchoscopy instruments should address this limitation.

4. Conclusion

The image-guided bronchoscopy system was effective for sampling peripheral sites, with planning, navigation, and yield results exceeding those of previously reported studies.

References

1. M. Y. Dolina, D.C. Cornish, S.A. Merritt, L. Rai, R. Mahraj, W.E. Higgins, and R. Bascom. Interbronchoscopist variability in endobronchial path selection: A simulation study, Chest 133 (4) (2008) 897–905.
2. C.S. White, E.A. Weiner, P. Patel, and E.J. Britt. Transbronchial needle aspiration: guidance with CT fluoroscopy, Chest 118 (6) (2000) 1630–1638.
3. T.R. Gildea, P.J. Mazzone, D. Karnak, M. Meziane, and A.C. Mehta. Electromagnetic navigation diagnostic bronchoscopy: A prospective study. Am J Respir Crit Care Med 174 (9) (2006) 982-989.
4. F. Asano, Y. Matsuno, N. Shinagawa, K. Yamazaki, T. Suzuki, and H. Moriya. A virtual bronchoscopic navigation system for pulmonary peripheral lesions, Chest 130 (2) (2006) 559–566.
5. N. Shinagawa, K. Yamazaki, Y. Onodera, F. Asano, T. Ishida, H. Moriya, and M. Nishimura. Virtual bronchoscopic navigation system shortens the examination time—feasibility study of virtual bronchoscopic navigation system, Lung Cancer 56 (2) (2007) 201–206.
6. S. A. Merritt, J.D. Gibbs, K. Yu, V. Patel, L. Rai, D.C. Cornish, R. Bascom, and W.E. Higgins. Real-time image-guided bronchoscopy for peripheral lung lesions: A phantom study, Chest 134(5) (2008) 1017-1026.
7. M.W. Graham, J.D. Gibbs, K. Yu, D.C. Cornish, M.S. Khan, R. Bascom, and W.E. Higgins. Image-Guided Bronchoscopy for Peripheral Nodule Biopsy: A Human Feasibility Study, Am J Respir Crit Care Med 177 (abstracts issue) (2008) A893.

Acknowledgments

This work was funded by NIH NCI grants #CA074325 and CA091534.